Internal Medicine
The Japanese Society of Internal Medicine
doi: 10.2169/internalmedicine.7566-26
Intern Med Advance Publication
http://internmed.jp

【 REVIEW ARTICLE 】

Abdominal Pain Before Rash in Immunocompromised Patients: A Narrative Review of a Visceral Disseminated Varicella-Zoster Virus Infection

Yoshitaka Furuto and Yuko Shibuya

Abstract:

Visceral disseminated varicella-zoster virus (VZV) infection is an uncommon, but potentially life-threatening complication in immunocompromised patients and it may initially present with severe abdominal pain before any rash appears. This narrative review, supported by a structured PubMed search through March 2026, aimed to characterize such abdominal-pain-first presentations and identify practical clues for making earlier diagnosis. We integrated the findings from a previously published illustrative case meeting the review focus. Across the available literature, recurrent features included severe abdominal pain disproportionate to the abdominal findings, a delayed or absent rash at presentation, limited or non-diagnostic computed tomography findings, and periarterial fat stranding around the celiac artery or superior mesenteric artery in some reports. In immunocompromised patients with severe unexplained abdominal pain, a visceral disseminated VZV infection should be included in the differential diagnosis. Repeated skin examinations, early blood VZV-DNA testing, prompt intravenous aciclovir, and a reduction of immunosuppression when feasible may facilitate both earlier recognition and treatment.

Key words: varicella-zoster virus, disseminated herpes zoster, abdominal pain, immunocompromised host, diagnostic delay

(Intern Med Advance Publication)
(DOI: 10.2169/internalmedicine.7566-26)

Introduction

Acute abdominal pain in immunocompromised patients prompts an urgent evaluation for immediately life-threatening conditions, including perforation, mesenteric ischemia, bowel obstruction, pancreatobiliary emergencies, thrombosis, and an invasive infection. However, not all clinically important causes of severe abdominal pain present with clear peritoneal signs or convincing structural abnormalities on the initial imaging. Among these less readily recognized causes, visceral disseminated varicella-zoster virus (VZV) infection should be considered because it is potentially life-threatening, treatable, and it may initially present before the appearance of a characteristic rash (1).

In susceptible hosts, severe abdominal pain may precede cutaneous eruption and mimic acute abdomen, thus creating a vulnerable diagnostic window during which antiviral treatment may be delayed. This presentation is biologically plausible because VZV reactivation begins in the neural tissue and it may produce pain before vesicular skin lesions become clinically evident (2). In addition, blood VZV-DNA may become detectable before any rash appears, providing a potential route for a pre-eruptive diagnosis in selected cases (3).

Published reports suggest that this abdominal pain-first presentation is not limited to isolated anecdotal cases. In a review of reported cases, rash followed abdominal pain by a mean of 6.5 days, was absent in a minority of patients, and mortality remained substantial (4). More recent reports from nephrology, rheumatology, and transplant settings have described the same clinical pattern in immunocompromised patients (5-12). These observations support the clinical importance of early recognition, particularly when severe pain

Department of Hypertension and Nephrology, NTT Medical Center Tokyo, Japan
Received: March 22, 2026; Accepted: April 30, 2026; Advance Publication by J-STAGE: June 18, 2026
Correspondence to Dr. Yoshitaka Furuto, furuto19761006@yahoo.co.jp

Table. Representative Reports of Visceral Disseminated Varicella-zoster Virus Infection with Abdominal Pain Preceding Rash Or without Rash at Initial Presentation.

First author, year	Study type	Host context / immunosuppression	Abdominal pain before rash	Rash at initial presentation	CT clue	VZV confirmation method	Outcome	Principal relevance to this review
Timotijevic, 2025 (1)	Scoping review	156 cases of disseminated VZV with internal organ involvement; predominantly immunocompromised hosts	Variable	Variable; absent in a minority	Not the main focus	Review of published cases	Mixed	Broad overview showing that internal organ involvement predominantly affects immunocompromised patients and remains associated with substantial mortality
Tsuji, 2017 (4)	Case report with literature review	Granulomatosis with polyangiitis after rituximab and prednisolone	Yes	Absent	Not a central feature	Clinical diagnosis; literature review	Survived; review included fatal cases	Highlights delayed rash appearance, rash absence in a minority, and continued mortality in abdominal-pain-first cases
Ishino, 2023 (5)	Case report	Systemic lupus erythematosus receiving immunosuppressive therapy	Yes	Appeared later	Not a central feature	Clinical diagnosis	Survived	Illustrates that early recognition and treatment may be lifesaving in rheumatologic immunosuppression
Takehara, 2025 (6)	Case report with literature review	Lupus nephritis during remission induction therapy	Yes	Appeared later	Not a central feature	Clinical diagnosis	Fatal	Shows that fulminant courses remain possible during intensive immunosuppression
Yamamuro, 2025 (7)	Retrospective study	Organ transplant recipients	Variable	Variable	Not a central feature	Retrospective clinical analysis	Mixed	Supports transplant recipients as a persistently high-risk host group
Furuto, 2019 (8)	Case report	Membranous nephropathy treated with prednisolone, mizoribine, and cyclosporine	Yes	Absent	Increased fat density around the celiac artery and SMA root	Blood VZV-DNA PCR	Survived	Illustrative PCR-confirmed case showing abdominal pain, soft abdomen, and periarterial CT change before rash
Habuka, 2018 (9)	Case report	Lupus nephritis and rheumatoid arthritis; mycophenolate mofetil and high-dose glucocorticoids	Yes	Appeared later	Not a central feature	Clinical diagnosis	Fatal	Demonstrates catastrophic progression under combined high-grade immunosuppression
Loftus, 2019 (10)	Case report	Renal transplant recipient	Yes	Appeared later	Not a central feature	Clinical diagnosis	Fatal	Reinforces renal transplantation as a high-risk setting for delayed recognition
Spernovasilis, 2021 (11)	Case report	Psoriatic arthritis treated with infliximab biosimilar and steroids	Yes	Absent	Not a central feature	Clinical diagnosis	Survived	Shows that severe abdominal pain without rash may occur in biologically immunosuppressed patients
Wang, 2021 (12)	Case report	Renal transplant recipient	Yes	Appeared later	Not a central feature	Clinical diagnosis	Fatal	Emphasizes the potential lethality of delayed recognition in transplant recipients
Matsumoto, 2025 (13)	Case series / imaging-focused report	Patients with visceral disseminated VZV infection; emphasis on imaging findings	Variable	Variable	Periarterial fat stranding	Clinical diagnosis with imaging emphasis	Variable	Supports periarterial fat stranding as a recurrent and potentially useful early imaging clue
Takada, 2020 (14)	Case report	Patient receiving pomalidomide	Yes	Appeared later	Periarterial fat stranding	Clinical diagnosis	Survived	Included primarily because it supports the diagnostic relevance of periarterial fat stranding
Fehr, 2002 (15)	Case series with literature review	Adult renal allograft recipients	Variable	Variable	Not a central feature	Case series and literature review	Mixed	Early evidence that renal allograft status is a major host-risk context for disseminated VZV
Yagi, 2000 (16)	Case report	Allogeneic bone marrow transplantation	Yes	Absent	Not a central feature	Clinical diagnosis with response to acyclovir	Survived	Demonstrates that acute abdomen without rash can represent visceral VZV and may justify empiric acyclovir when suspicion is high

The Table Summarizes Study Type, Host Background, Timing of Rash Relative to Abdominal Pain, Computed Tomography Findings, Method of VZV Confirmation, Clinical Outcome, and the Principal Relevance of Each Report to the Diagnostic Framework of This Review. Reports were Selected to Illustrate Recurrent Clinical Features Relevant to Early Recognition in Immunocompromised Patients; Some Articles were Included Primarily because They Provided Useful Imaging Or Diagnostic Information.

is accompanied by limited abdominal findings and non-diagnostic computed tomography (CT) findings.

This narrative review aimed to characterize the clinical features of visceral disseminated VZV infection in immunocompromised patients in whom abdominal pain precedes rash and to identify practical clues that may support an earlier diagnosis in general internal medicine settings. To do so, we conducted a narrative review supported by a structured PubMed search and integrated the findings from a previously published illustrative case that fulfilled the clinical focus of this review (8). Our goal was not to define a new disease entity, but to clarify a recurrent and clinically important presentation pattern that may otherwise be overlooked. The representative reports are summarized in Table.

Methods

Review design

This article was designed as a narrative review supported by a structured literature search which focused on abdominal pain preceding rash in immunocompromised patients with a visceral disseminated varicella-zoster virus infection. The review was informed by a previously published illustrative case from our institution, which was included because it met the clinical focus of the review and provided detailed virologic and imaging findings relevant to the early diagnosis of this condition (8).

Literature search strategy

We searched PubMed for relevant English-language reports from database inception to March 2026. The search terms included combinations of "varicella-zoster virus" or "herpes zoster" with "visceral," "disseminated," "abdominal pain," "acute abdomen," "sine herpete," "immunocompromised," "immunosuppressed," and "PCR." We also manually reviewed the reference lists of the selected reports to identify any additional relevant articles.

Eligibility and study selection

We considered articles to be eligible if they described at least one of the following in human subjects: 1) abdominal pain preceding the appearance of a rash, 2) the absence of a rash at initial presentation, 3) a visceral or disseminated VZV infection in immunocompromised hosts, or 4) imaging or virologic findings relevant to the early diagnosis of a visceral disseminated VZV infection. Case reports, case series, retrospective studies, and clinically relevant review articles were considered when they directly informed the abdominal pain-first diagnostic framework of this review. Titles and abstracts were screened for relevance to pre-eruptive, rash-absent-at-presentation, visceral, or disseminated VZV. Potentially relevant articles were then subjected to full-text assessment. Reports lacking sufficient clinical details or without clear relevance to abdominal or visceral presentations were excluded from the descriptive synthesis. The search and manual reference review identified 17 potentially relevant reports for full-text assessment; after the exclusion of one report that did not sufficiently match the immunocompromised host focus of the present review. As a result, 16 reports were thus retained in the final descriptive synthesis.

Data extraction and descriptive synthesis

From each included report, we extracted information on the host background, immunosuppressive context, abdominal pain preceding rash, rash status at initial presentation, CT findings, virologic confirmation method, study type, and clinical outcomes. Because the available literature consisted largely of heterogeneous case-based reports, we performed a descriptive narrative synthesis rather than a formal quantitative analysis. Representative reports that were the most informative for clinical recognition are summarized in Table.

Terminology used in this review

In this review, we used the term "visceral disseminated VZV infection" to describe disseminated VZV infection with internal organ involvement or a clinically compatible visceral syndrome in immunocompromised patients. We used the terms "pre-eruptive" or "rash-absent at presentation" to describe cases in which abdominal pain preceded the appearance of typical cutaneous lesions. Because "zoster sine herpete" classically refers to VZV reactivation without a rash, we did not use this term as a universal label for all abdominal pain-first cases.

Clinical Features of Abdominal-Pain-First Presentation

The current literature suggests a recurrent clinical pattern in which visceral disseminated VZV infection presents with severe abdominal pain before any rash becomes clinically evident. A common feature across reported cases is pain that appears disproportionate to the abdominal findings. Patients may present with intense epigastric or diffuse abdominal pain, while guarding, rebound tenderness, or marked peritoneal irritation is minimal or absent (4-16).

Another important feature is a delayed or initially absent rash. This is often the element that complicates diagnosis the most because it removes the most recognizable clinical clue at the time when abdominal pain first prompts medical attention (1, 4, 11, 12, 16). In some cases, systemic abnormalities such as thrombocytopenia, transaminase elevation, elevated lactate dehydrogenase, or coagulopathy may be present during this visceral phase, despite limited localizing abdominal findings (1, 5-10, 12).

Taken together, these reports suggest that severe abdominal pain before rash in an immunocompromised patient should not be dismissed as clinically inconsistent with VZV simply because the abdomen is soft or early imaging is unrevealing. This combination may represent a clinically important pre-eruptive presentation pattern.

Factors Contributing to a Diagnostic Delay

The diagnosis is often delayed because clinicians are trained to associate VZV primarily with a rash, whereas the visceral syndrome may first become clinically apparent through pain. In the pre-eruptive phase, abdominal pain is easily interpreted within a structural abdominal framework, especially when the patient is acutely ill and immunocompromised. As a result, there is a vulnerable interval during which the disease is biologically active, but the most familiar diagnostic clue has not yet appeared.

The second reason for the delay is interpretive. When pain is striking, but the abdomen remains soft and CT does not reveal perforation, obstruction, or ischemia, then clinicians may remain anchored to conventional structural explanations for too long. In this setting, the coexistence of se-

vere pain, limited abdominal findings, and non-diagnostic imaging should prompt reconsideration of the differential diagnosis rather than reassurance.

Imaging and Laboratory Clues

Among the imaging findings, periarterial fat stranding around the celiac or superior mesenteric artery has emerged as a recurrent and potentially useful early clue (8, 13, 14). This finding is not specific in isolation, but in an appropriate host context, it may support a suspicion of visceral disseminated VZV infection rather than being dismissed as incidental. The literature suggests that such periarterial changes may appear even when CT is otherwise non-diagnostic for classic acute abdomen.

Laboratory abnormalities are similarly non-specific, but potentially informative in nature. Thrombocytopenia, transaminase elevation, coagulopathy, and elevated lactate dehydrogenase levels may indicate systemic viral injury or evolving multiorgan involvement (1, 5-10, 12). Although none of these findings are diagnostic on their own, their coexistence with severe unexplained abdominal pain in an immunocompromised patient may strengthen the clinical suspicion.

Although these imaging and laboratory abnormalities may support the suspicion of a diagnosis, none are sufficiently specific to establish the diagnosis in isolation. Their clinical value lies in prompting reconsideration of the differential diagnosis when severe abdominal pain remains unexplained in an immunocompromised host. Therefore, visceral disseminated VZV should be interpreted within a broader differential framework that includes other urgent viral, drug-related, and structural causes of abdominal pain.

A Differential Diagnosis in Immunocompromised Patients

Visceral disseminated VZV infection should be considered as part of a broader differential diagnosis rather than in isolation when immunocompromised patients present with severe abdominal pain before a rash. The first priority is the exclusion of immediately life-threatening structural diseases, including gastrointestinal perforation, bowel obstruction, mesenteric ischemia, pancreatobiliary emergencies, and intra-abdominal hemorrhage. However, when abdominal pain remains severe despite limited abdominal findings and CT does not provide a convincing structural explanation, then other non-surgical and infection-related causes should be reconsidered.

Viral etiologies deserve particular attention in immunocompromised hosts. Cytomegalovirus may cause abdominal pain through enterocolitis, hepatitis, pancreatitis, or ulcerative gastrointestinal disease (17). Although less commonly implicated, the herpes simplex virus may also cause visceral disease in severely immunosuppressed patients. Epstein-Barr virus-related disease may be considered in the differential diagnosis depending on the clinical context, especially when systemic inflammatory findings, hepatitis, lymphoproliferative disease, or transplant-related complications are present (18). Opportunistic fungal or bacterial infections may also produce abdominal symptoms with limited early localizing findings.

Drug-related conditions should also be considered. In patients receiving glucocorticoids, mycophenolate mofetil, calcineurin inhibitors, rituximab, or other immunosuppressive therapies, abdominal pain may reflect medication-related gastrointestinal toxicity, pancreatitis, hepatotoxicity, enterocolitis, or secondary infections facilitated by treatment-associated immune dysfunction. Accordingly, the diagnostic value of considering visceral disseminated VZV lies not in prematurely narrowing the differential diagnosis, but in appropriately widening it when severe pain, limited abdominal findings, delayed rash, and host-risk context create a pattern of clinical discordance.

In this setting, repeated skin examinations, careful reassessment of medication exposure, targeted viral testing, and a close re-evaluation of evolving laboratory and imaging abnormalities are important. Visceral disseminated VZV becomes particularly relevant when severe pain appears out of proportion to the abdominal findings, when rash is absent or delayed, and when subtle periarterial CT changes or unexplained systemic abnormalities such as thrombocytopenia, transaminase elevation, elevated lactate dehydrogenase, or coagulopathy are present.

Early Virologic Confirmation by Blood VZV-DNA PCR

One practical route for pre-eruptive confirmation is blood VZV-DNA testing. The classic report by de Jong et al. demonstrated that high concentrations of VZV DNA could be detected in the blood before the appearance of skin lesions, thereby enabling an earlier diagnosis and treatment (3). This proof-of-principle is supported by subsequent clinical experiences, including the previously published illustrative case included in this review (4, 5, 8, 12).

Importantly, not all reported cases were confirmed using blood or tissue PCR. Much of the literature relies on clinical diagnoses supported by subsequent rash appearance, host context, treatment response, or post hoc interpretation. Therefore, a negative or unavailable PCR result should not automatically exclude the diagnosis when clinical suspicion is high. Rather, blood VZV-DNA PCR should be viewed as an important adjunct that may strengthen diagnostic confidence during the pre-eruptive phase of the disease.

Clinical Implications for Internists

Once visceral disseminated VZV infection becomes clinically plausible, then prompt intravenous aciclovir is essential, and immunosuppression should be reduced when feasible and safe (1, 3-16). The key practical step is not the abandonment of structural reasoning, but the timely widening of the differential diagnosis when severe pain persists and the expected structural explanation does not emerge.In this setting, repeated skin examinations, early blood VZV-DNA PCR when available, and prompt intravenous aciclovir should be considered without waiting for a fully developed

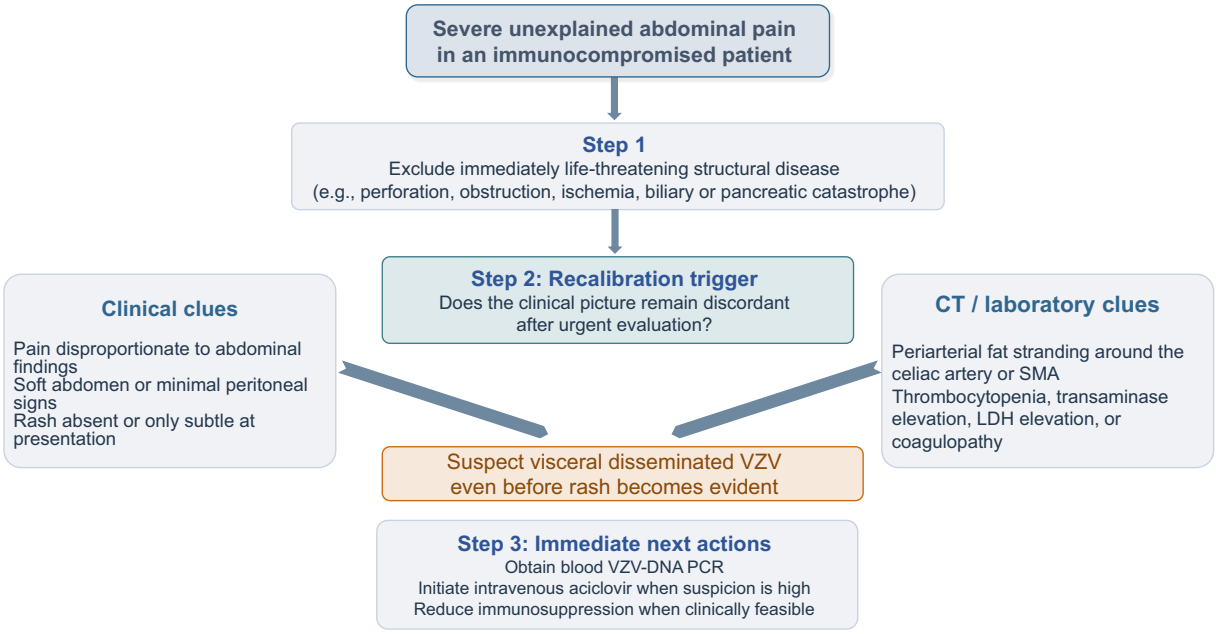

Figure. Practical diagnostic approach to visceral disseminated varicella-zoster virus infection in immunocompromised patients presenting with severe abdominal pain before rash. In immunocompromised patients with severe abdominal pain, life-threatening structural abdominal disease should be excluded. When abdominal findings are limited and computed tomography is non-diagnostic for classic acute abdomen, but it shows periarterial fat stranding around the celiac artery or superior mesenteric artery, visceral disseminated varicella-zoster virus infection should be considered, particularly when systemic abnormalities such as thrombocytopenia, transaminase elevation, elevated lactate dehydrogenase, or coagulopathy are present. In this setting, repeated skin examinations, blood VZV-DNA polymerase chain reaction, and prompt intravenous aciclovir should be considered without waiting for a full rash declaration. Abbreviations: CT, computed tomography; LDH, lactate dehydrogenase; PCR, polymerase chain reaction; SMA, superior mesenteric artery; VZV, varicella-zoster virus.

rash if the clinical suspicion is sufficiently high. An integrated practical diagnostic approach based on this sequence is illustrated in Figure.

Limitations

This review has some limitations. First, it was conducted as a narrative review supported by a structured PubMed search rather than as a formal systematic review. Therefore, some relevant reports may have been missed. Second, much of the available literature consists of case reports and small case series, which introduce publication bias and limit generalizability. Third, diagnostic confirmation was not uniform across all reports, and not all cases were confirmed by blood or tissue VZV polymerase chain reaction (PCR). Fourth, the included studies were heterogeneous with respect to underlying diseases, degree of immunosuppression, clinical severity, and reporting quality. Finally, some reports were included because they were particularly informative regarding imaging findings or the abdominal pain-first clinical pattern, even when the host background was not identical across all cases. Accordingly, the purpose of this review was not to establish incidence or causal estimates, but to clarify a clinically important presentation pattern that may help support earlier recognition in practice.

Conclusion

Visceral disseminated VZV infection should be included in the differential diagnosis when an immunocompromised patient presents with severe abdominal pain that is disproportionate to the abdominal findings and unexplained by conventional imaging. This presentation may occur before any rash becomes clinically evident, and CT may be non-diagnostic for classic acute abdomen despite containing subtle periarterial clues in some cases. Because a delayed recognition may postpone antiviral treatment, repeated skin examinations, early blood VZV-DNA testing when available, and prompt intravenous aciclovir should be considered when clinical suspicion is sufficiently high. Recognition of this abdominal pain-first presentation pattern may facilitate the earlier diagnosis and management in selected patients.

The authors state that they have no Conflict of Interest (COI).

Acknowledgement

The authors used ChatGPT (OpenAI) for the language refinement. All clinical interpretations, literature evaluations, and final drafting decisions were made by the authors.

Funding

No external funding was received for this work.

Ethics Approval

Not applicable.

Consent for Publication

Not applicable for this review article.

Data Availability

No new datasets were generated or analyzed in this study.

References

1. Timotijevic A, Kodela P, Glusac V, et al. Disseminated varicella-zoster virus infection with internal organ involvement: a scoping review of 156 cases. Viruses **17**: 1135, 2025.
2. Gershon AA, Breuer J, Cohen JI, et al. Varicella zoster virus infection. Nat Rev Dis Primers **1**: 15016, 2015.
3. de Jong MD, Weel JF, van Oers MH, et al. Molecular diagnosis of visceral herpes zoster. Lancet **357**: 2101-2102, 2001.
4. Tsuji H, Yoshifuji H, Fujii T, et al. Visceral disseminated varicella zoster virus infection after rituximab treatment for granulomatosis with polyangiitis. Mod Rheumatol **27**: 155-161, 2017.
5. Ishino Y, Fukasawa H, Kitamoto S, et al. A survival case of visceral disseminated varicella zoster virus infection in a patient with systemic lupus erythematosus. BMC Nephrol **24**: 164, 2023.
6. Takehara R, Ebihara I, Honda Y, et al. Fatal visceral disseminated varicella zoster virus infection during initial remission induction therapy in a patient with lupus nephritis: a case report and review of the literature. CEN Case Rep **14**: 477-485, 2025.
7. Yamamuro R, Romero A, Khandelwal-Young A, et al. Disseminated varicella-zoster virus infection in organ transplant recipients: a 10-year retrospective study. Transpl Infect Dis **27**: e70117, 2025.
8. Furuto Y, Kawamura M, Namikawa A, Takahashi H, Shibuya Y. Successful management of visceral disseminated varicella zoster virus infection during treatment of membranous nephropathy: a case report. BMC Infect Dis **19**: 625, 2019.
9. Habuka M, Wada Y, Kurosawa Y, et al. Fatal visceral disseminated varicella zoster infection during initial remission induction therapy in a patient with lupus nephritis and rheumatoid arthritis: possible association with mycophenolate mofetil and high-dose glucocorticoid therapy: a case report. BMC Res Notes **11**: 165, 2018.
10. Loftus MJ, Quastel M, McFarlane PA, et al. Fatal disseminated visceral varicella zoster virus infection in a renal transplant recipient. Transpl Infect Dis **21**: e13062, 2019.
11. Spernovasilis N, Raissaki M, Papakitsou I, et al. Visceral varicella-zoster virus infection presenting with severe abdominal pain without a rash in a patient with psoriatic arthritis treated with infliximab biosimilar and steroids: a case report. Mediterr J Rheumatol **32**: 280-284, 2021.
12. Wang D, Wang JQ, Tao XG. Fatal visceral disseminated varicella-zoster virus infection in a renal transplant recipient: a case report. World J Clin Cases **9**: 9168-9173, 2021.
13. Matsumoto Y, Ogawa K, Hirakawa H, et al. Periarterial fat stranding as a diagnostic marker for visceral disseminated varicella-zoster virus infection. Intern Med **64**: 1926-1932, 2025.
14. Takada H, Kohara S, Ito T, et al. Disseminated varicella zoster infection with abdominal pain and periarterial fat stranding in a patient taking pomalidomide. Acute Med Surg **7**: e494, 2020.
15. Fehr T, Bossart W, Wahl C, Binswanger U. Disseminated varicella infection in adult renal allograft recipients: four cases and a review of the literature. Transplantation **73**: 608-611, 2002.
16. Yagi T, Karasuno T, Hasegawa T, et al. Acute abdomen without cutaneous signs of varicella zoster virus infection as a late complication of allogeneic bone marrow transplantation: importance of empiric therapy with acyclovir. Bone Marrow Transplant **25**: 1003-1005, 2000.
17. Yeh PJ, Wu RC, Chiu CT, et al. Cytomegalovirus diseases of the gastrointestinal tract. Viruses **14**: 352, 2022.
18. Zhang H, Zhao S, Cao Z. Impact of Epstein-Barr virus infection in patients with inflammatory bowel disease. Front Immunol **13**: 1001055, 2022.

The Internal Medicine is an Open Access journal distributed under the Creative Commons Attribution-NonCommercial-NoDerivatives 4.0 International License. To view the details of this license, please visit (https://creativecommons.org/licenses/by-nc-nd/4.0/).

Ⓒ The Japanese Society of Internal Medicine
Intern Med Advance Publication